

Expert Discussion on Challenges in C3G Diagnosis: A Podcast Article on Best Practices in Kidney Biopsies

Richard Lafayette & Vivek Charu

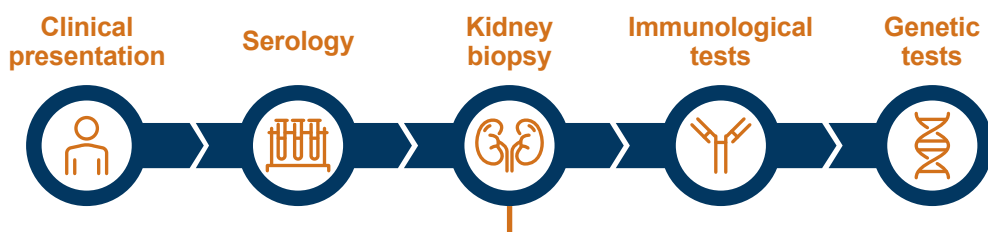
What is C3G?

A rare and progressive complement-mediated kidney disease which is **challenging to diagnose** due to **clinical heterogeneity**. The term C3G comprises **two subtypes**: C3GN and DDD

How is C3G diagnosed?

Definitive diagnosis of C3G requires a **kidney biopsy** and **dominant C3 staining** in the glomeruli using **immunofluorescence**

Diagnostic workflow

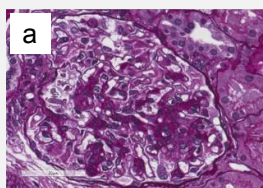


LIGHT MICROSCOPY

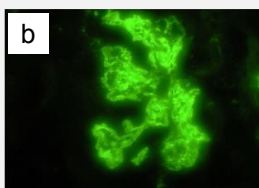
IMMUNO-FLUORESCENCE

ELECTRON MICROSCOPY

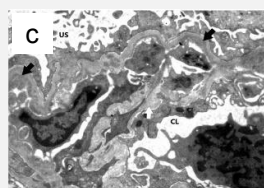
C3GN



a) PAS-positive, segmental mesangial proliferation

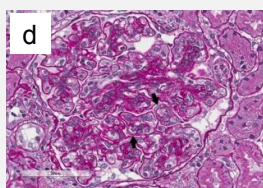


b) Coarsely granular mesangial and glomerular capillary wall C3 deposits

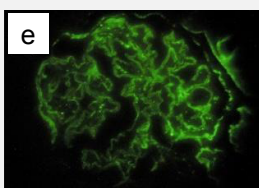


c) Subendothelial electron dense deposits (black arrows) with newly formed lamina densa

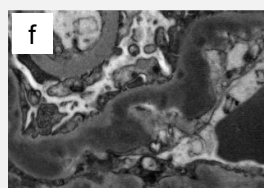
DDD



d) Thickened PAS-positive glomerular basement membranes with double contours (black arrows)



e) Ribbon-like pattern of C3 deposition along glomerular basement membrane



f) Highly osmiophilic electron dense deposits permeating the lamina densa

Images reprinted with permissions from Schena FP, et al. *Int J Mol Sci.* 2020;21:525. Magnification: Immunofluorescence 400x; electron microscopy x8900.

An accurate diagnosis of C3G requires **clinical-pathologic correlation** and close **communication between the nephrologist and pathologist** to rule out differential diagnoses such as infection-related glomerulonephritis

C3G, C3 glomerulopathy; C3GN, C3 glomerulonephritis; CL, capillary lumen; DDD, dense deposit disease; PAS, periodic acid-Schiff; US, urinary space.

This graphical abstract represents the opinions of the authors. For a full list of declarations, including funding and author disclosure statements, and copyright information, please see the full text online. Prepared by Ella Brooks (BOLDSCIENCE Ltd.) and was funded by Novartis Pharmaceuticals Corporation.

 **Adis**

PEER-REVIEWED
FEATURE

 OPEN
ACCESS